ATLANTIS PRESS

Advances in Health Science Research, volume 10

1st International Integrative Conference on Health, Life and Social Sciences (ICHLaS 2017)

Burn Healing with Binahong (Anredera cordifolia (Tenore) Steenis) Leaves Extract as A Topical and Systemic Treatments

Ayu Fitri Hapsari, Wardhani RP, Alfina A, Dzakiy WA, Ginting RB
Medical Program, Faculty of Medicine and Health Sciences,
Syarif Hidayatullah State Islamic University
Jakarta, Indonesia

Diah Ayu Woro Setyaningrum
Department of Anatomic Pathology, Faculty of Medicine,
Trisakti University
Jakarta, Indonesia

***Abstract*—Burn is still an important problem in health facility worldwide. Burns management from ancients ago until now is quite varied either giving topical therapy alone or combination with systemic drug along with various clinical considerations. Research on the healing of burns with phytoextract has been done in the last 20 years. Binahong leaves or *Anredera Cordifolia (Tenore) Steenis* is one of the most studied phytoextract for wounds, but lack on burns research. Previous studies in this leaf ethanol extract showed that 40% concentration is the most effective on wound healing. Describes the effect of binahong 40% leaves ethanolic extract in the formation of reepithelialization, neo-vascularization, fibroblasts, and the density of collagen as part of healing process on post second degree burns of the skin as topical and systemic/oral treatments. Experimental study on 25 *Sprague dawleys* that divided into 5 groups. Group I was treated with ointment of binahong 40% leaves ethanolic extract, group II was treated with oral preparation of binahong leaves ethanolic extract 100mg/kg body weight, group III was treated with combination of binahong 40% leaves ethanolic extract both topical and oral preparations, group IV was treated with a silver sulfadiazine ointment (positive control), and group V was treated with ointment base (negative control). Treatment was started after second-degree burns created on each rat for 6 days. Burns site excised after six days of treatments, prepared for paraffin embedded and HE staining to examine tissue reepitelialization, neo-vascularisations, fibroblast count, collagen formation, and inflammatory cell formation using light microscope. There was no significant difference in the process of reepithelialization, neo-vascularization, the amount of fibroblasts, among five groups ($p > 0.05$). While the lowest inflammatory cells and the density of collagen were best seen in the 40% extract ointment group with $p = 0, 0001$ and $p = 0.037$ ($p < 0.05$). The process of burns healing with topical and oral binahong extracts did not show any significant difference, but topical administration was able to suppress the number of inflammatory cells and increase collagen formation more effective than sistemic/oral treatments alone.**

Keywords*— *Binahong leaves extract; Anredera cordifolia (Ten.) Steenis; burn healing;topical treatment; systemic treatment.

I. INTRODUCTION

Burn is still an important problem in health facility worldwide. Burns management from ancients ago until now is quite varied either giving topical therapy alone or combination with systemic drug along with various clinical considerations. Burns can caused by direct exposed of fire, electrocution, burn scalded, or chemical burn. About 78% burns cases in Indonesia caused by direct exposed from fire [1].

There are varies research on the healing of burns with phytoextract or other alternatives has been done at least in the last two decades, if not more. Somboonwong, et al in 2012 report that extract of Centella asiatica has a positive effects in wound healing, either incision and burn injury [2]. Study conducted in 1998 for superficial burn wound showed that repair activity of honey dressing better than silver sulfadiazine. Reparative activity was assessed with histological evidence by examination of epithelialization and inflammation response [3].

As for binahong leaves and its extract, has also been examined the effect on wound healing. Study on binahong leaf paste has positive effect on wound contraction in clean incision wound [4].

Study on etanolanic extract of binahong leaves in guinea pig showed wound healing activity on incision lesion and had better effect at concentration 20% and 40% compared to povidone iodine [5].

Anredera cordifolia (Ten) Steenis has several common names such as Madeira vine, mignonette vine, lamb's tail or known as Binahong in Indonesia [6,7]. In Indonesia, its custom from generations to generation that binahong leaf was used as cure in skin injury. They use binahong leaf in traditional way by crushed and attached to injury site of the skin [8].

People of Javanese Indonesia believed that Binahong plant can cure several diseases beside wound healing such as diabetes mellitus, hypertension, rheumatics, typhoid fever, tuberculosis, asthma and many more. Unfortunately, those benefits were not well reported and documented [9].

Binahong leaves also used as herbal medicine with many active properties such as phenol in its leaves also had been used as antibiotic against gram positive and negative bacteria in treatment of sexual transmitted disease [10].

The most common and important component of Anredera cordifolia (Ten) Steenis is saponins that has role in treating those diseases mention above and also for maintain body health [9].

Binahong leaves extract also proven have role in healing of hematome [11] and improving renal failure [12] in rats by oral administration. The fibroblasts begin to appear on the third day on oral administration of binahong extract, while topical administration only appear on seventh day [11]. Those studies raises the question, whether oral and topical administration of binahong extract also has a different effect on burn wound healing, and the combination of both administration.

We made previous study that comparing the effect of binahong leaves extract in burn healing in different concentration, and the result showed that 40% concentration of binahong leaves extract has the most effective role compare to 10% and 20% Binahong leaves extract.

The aim of this study is to describe the effect of 40% binahong leaves ethanolic extract in the formation of reepithelialization, neo-vascularization, the amount of fibroblasts, and the density of collagen as part of healing process on post second degree burns of the skin as topical and systemic/oral treatments.

II. MATERIAL AND METHODS

A. *Binahong Leaves Ethanolic Extract*

Binahong leaves was determined first at Research Center for Biology, Indonesian institute of Sciences, Bogor, Indonesia. Binahong leaves extract was prepared at Research Institute for Spices and Medicinal Plants, Agricultural Research and Development Agency, Ministry of Agriculture of Republic of Indonesia. Thick extract was obtained after extraction with 96% ethanol solution.

B. *Binahong Leaves Extract Ointment Preparation*

The ointment preparations used in this study consisted of adeps lanae and vaseline album (base of ointment) and add with Binahong leaves extract to reach concentration of 40%.

C. *Binahong Leaves Extract Suspension Preparation*

Binahong leaves extract oral dose that recommended are 50-200 mg/kg body weight [12,13] in this study we use 100 mg/kg body weight. Oral suspension preparations use distilled water, Sodium Carboxymethyl Cellulose and binahong leaf extracts. Sodium Carboxymethyl Cellulose has function as a thickening agent, stabilizer and suspending agent [14].

D. *Second Degree Thickness Burn on Rats*

The rats were anesthetized with the ether inhalation. The rats' backs were shaved in the size of 4 cm × 3 cm and smeared with betadine. The burn wound made by pressing the iron plate with the size of 3 cm × 2 cm that has been heated in 99°C boiling water for 10 min. The burns were made on the back of the rats by patching the iron plate on the rats back for 30 sec [15].

E. *Burn Treatment on Rats*

A total of 25 male, Sprague dawley rats were put randomly in five groups, each groups receiving different treatments. The treatments are:
P1: Rats with skin burns, treated with extract ointment.
P2: Rats with skin burns, treated with extract oral suspension.
P3: Rats with skin burns, treated with extract ointment and oral suspension.
K+: Rats with skin burns, treated with silver sulfadiazine.
K-: Rats with skin burns, treated with ointment base (mixture of adeps lanae and Vaseline album).
The treatment was carried out topically by smearing the leaf extract ointment and silver sulfadiazine using clean cotton buds. The treatment was conducted twice daily with an interval of 12 h between treatments for 5 days.

F. *The Histopathological Slides Preparation and microscopic observation*

The small excision in the burned area of skin rats was conducted at the end of the experiment and followed with preparation of histopathologic slides. Tissue samples were fixed in 10% formalin solution, and continued with making preparation of tissue embedded slides in 4 μm thickness and tissue processing for staining. The observed histologic parameters were reepithelization inflammation cells infiltration, collagen deposit thickness, fibroblast, and angiogenesis on the wound biopsy specimens were determined. The specimens were stained with Masson's trichrome to observed collagen deposit thickness, and HE (Hematoxylin and Eosin) staining to observed other parameters.

Each slides observed by two independent observer performed in 10 consecutive field of view with magnification 40x objective lens using Olympus BX41 microscope.

Each slides was calculated the average of reepithelialization thickness that measured from each edges of wound; the average number of inflammation cells to observe inflammation cells infiltration; the average number of new vascularization; and the average number of fibroblast. Microscopic slides were photographed then calculated with the application of Image J.
Statistical analysis was using SPSS version 16.0 for windows. Homogeneity test by Levene's test, followed by normality test by Shapiro-Wilk, and one way Anova to compare variables in each group.

III. RESULT

The skin of rats that has been burned with an iron plate heated at 99° C for 30 seconds formed a 2nd degree burn shown in the figure below. The microscopic preparation of the image comes from the excised skin tissue immediately after the treatment of burns.

Second degree burns or partial thickness burn wounds are characterized by the depth of burns above the hypodermis. Figure 1 shows the structure of muscle and blood vessels are intact.

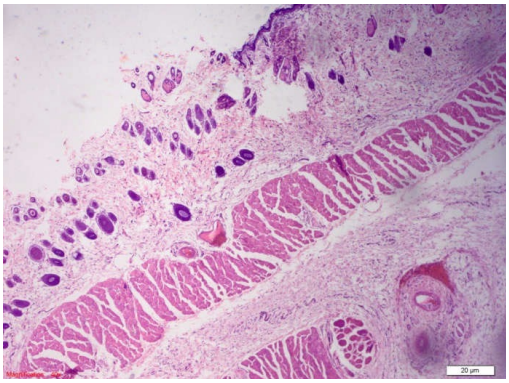

Fig. 1. Partial thickness (2nd degree) burn wound (magnification 10x objective lens).

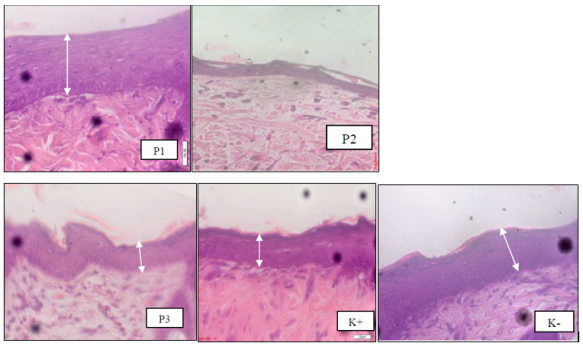

Fig. 2 Microscopic images P1, P2, P3, K + and K- with 40x magnification. The arrows indicate one of the measurement areas. To obtain the re-epithelization layer thickness data is used image application J v. 1.50i.

Based on the data presented in figure 3, it can be concluded that in P1 or treatment 1, the treatment of ointment extract of binahong leaves of 40% concentration has the highest thickness of re-epithelization with mean of thickness is 43.45 µm, while P2 is the treatment of binahong leaf extract orally has the lowest re-epithelial layer thickness with mean of thickness is 28.46 µm.
Neovascularization formed in the negative control treatment group, that was treat with the base of ointment containing adeps lanae and vaseline albums without binahong leaf extract was higher than in the other treatment groups.

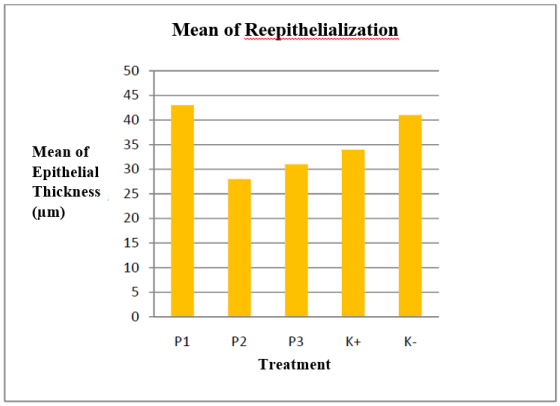

Fig. 3. The average of reepithelialization

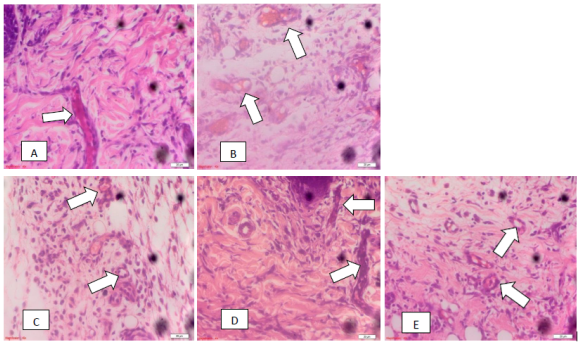

Fig 4. Neovascularization in five group of treatment: (A) extract binahong ointment, (B) extract binahong suspension, (C) combination of suspension and ointment, (D) positive control, (E) negative control.

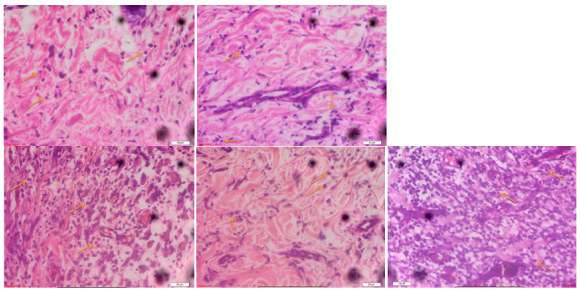

Fig 5. Microscopic images of inflammatory cells in burn tissues.

The highest number of inflammatory cell was found in negative control group which is without extract of the binahong leaf.

The number of fibroblasts between five groups after tested by one way ANOVA did not show any significant difference in all groups ($p>0.05$) although all treatment groups showed a higher mean score than the control group either positive or negative.

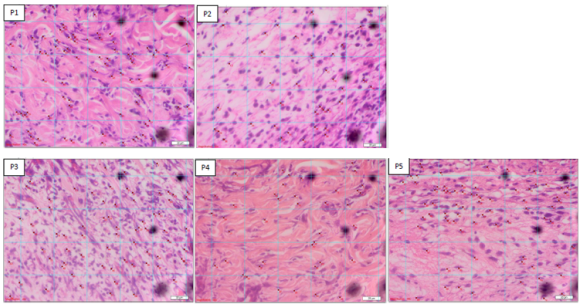

Fig 6. Microscopic images of fibroblast in burn tissues and its appearance in image J application.

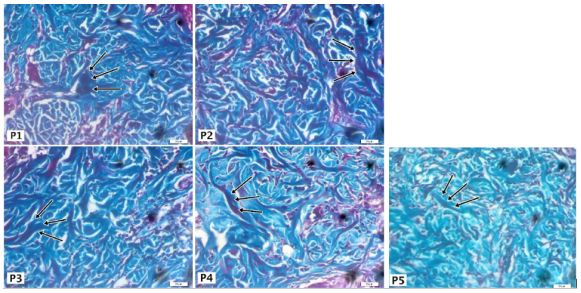

Fig. 7. Microscopic images of collagen from samples that stained with Mallory Trichrome.

Collagen density was analyzed qualitatively by measuring blue uptake in preparing photographs using Adobe Photoshop CS 6.0 application. The unit used is pixels. The measurement results are then averaged at each group.

Calculation results of collagen density and it statistical analysis showed that in groups with binahong extract ointment had the highest collagen density compared to other groups ($p < 0.05$).

IV. DISCUSSION

In burns treated with binahong leaf extract 40% ointment resulted in a thicker re-epithelization layer (mean re-epithelization thickness = 43.44 µm) compared with other treatment groups ($p > 0.05$).

This is due to the work of the binahong active substance, which is not present in the control group. Based on research conducted by Astuti, 2011, most phytochemical compounds found in binahong plants are saponins, these compounds are found in tubers and leaves [9]. In another study it was mentioned that saponins can stimulate the proliferation of epidermal cells and affect the acceleration of keratinocyte migration to the suffered an injury. This of course affects the acceleration of wound epithelialization. Other compounds that may affect the activation of epidermal keratinocytes are oleanic acid and ursolic acid, both of which are also present in binahong plants. Both of these compounds work to stimulate keratinocyte differentiation through their activation of PPAR (peroxisome proliferation-activated receptor) [16]. It is proven that the presence of active substances in binahong makes it capable of optimizing the wound re-epithelialization process.

Fat-based ointments help the drug prolong contact with the skin and also as a wound cover [17]. Closure of the wound will cause continuous contact injuries with proteinases, chemotaxics, complement and growth factors, which will disappear when the wound is exposed. So wound closure is useful for accelerating reepitelization, collagen synthesis, and increased angiogenesis by creating a hypoxic condition at the wound base and lowering the pH of the wound so that it will decrease the incidence of infection [18].

Vitamin C in binahong aside from improving the function of neutrophils and fibroblasts will also encourage the formation of neovascularization and strengthen [19]. Binahong leaves also contain active substances that Quercetin can increase the formation of neovascularization by inhibiting HIF prolyl-hydrocylase which resulted in activation of HIF-1 (Hypoxia-Inducible Factor-1) that activates transcriptions of several angiogenic genes and their receptors such as VEGF. VEGF activation will facilitate endothelial cell recruitment in hypoxic sites resulting in increased endothelial cell proliferation by regulating genes involved in cell cycle and DNA replication and ending with stimulation of neovascularization formation [20]. Leaf binahong extract in the wound healing phase plays a role in the hemostasis phase.

Saponin also inhibit phospholipase so that cell membrane phospholipids are not converted to arachidonic acid where arachidonic acid later with the help of cyclooxygenase enzymes will be converted to prostaglandins. The function of prostaglandin leukotrien and lipoxin is as potent chemokine to stimulate the migration of inflammatory cells to the wound site. Since the mechanisms of all chemokines are inhibited by saponins, the saponin effect is shown here as an antiinflammatory effect.

Binahong leaves also contain active compounds called oleanic acid (oleanic acid). Oleanic acid works as an anti-inflammatory by inhibiting COX-2 in the absence of prostaglandin formation that serves as chemoatractant for inflammatory cell migration. In addition oleanic acid will also inhibit 5-lipoxigenase thereby inhibiting the formation of leukotriene from arachidonic acid that serves as a potent chemotaxis for inflammatory cells. As a result the inflammatory reaction becomes shorter and the formation of collagen increases so that wound healing occurs perfectly [21].

Other active ingredients contained in Binahong leaves is flavonoids. Flavonoids have antiinflammatory activity like saponins by inhibiting cyclooxygenase and lipooksigenase to lessen inflammatory cells that migrate to the wound site, so the inflammatory reaction becomes shorter and the proliferative ability of TGF-β is not inhibited. TGF-β plays a role in migratory stimuli and fibroblast proliferation. Fibroblasts will synthesize collagen which will support the structure of the region undergoing wound healing process [22].

V. CONCLUSION

Binahong leaf extract affected the skin re-epithelization, the formation of fibroblast and collagen and shortened the inflammatory reaction post second grade burns of *Sprague dawley* rat especially on binahong ointment, compared to the combination of ointment and oral.

Although the process of burns healing with topical and oral binahong extracts did not show any significant difference, but topical administration was able to suppress the number of inflammatory cells and increase collagen formation more effective than sistemic/oral treatments alone.

REFERENCES

[1]. - Bureau for health research and development. Basic Health Research (Badan penelitian dan pengembangan kesehatan. Riset Kesehatan Dasar). 2013. Lap Nas 2013. 2013. doi:1 Desember 2013. Available: http://www.depkes.go.id/resources/download/general/Hasil%20Riskesdas%202013 (Accessed: June 23, 2016)

[2]. J. Somboonwong, M. Kankaisre, B. Tantisira, M.H. Tantisira MH, "Wound healing activities of different extracts of *Centella asiatica* in incision an burn wound model: an experimental animal study," BMC Complememtary Altern. Med, vol. 12, no. 103, pp. 1-7, Jul 2012

[3]. M. Subrahmanyam, "A prospective randomized clinical and histological study of superficial burn wound healing with honey and silver sulfadiazine," Burns, vol. 24, no. 2, pp. 157-61, Mar 1998.

[4]. G. Kaur, N.V. Utami, H.A. Usman, "Effect of topical application of Binahong (Anredera cordifolia (Ten.) Steenis) leaf paste in wound healing process in mice," Althea Medical Journal, vol. 1, no. 1, pp. 6-11, 2014

[5]. I. Miladiyah, B.R. Prabowo, " Ethanolic extract of Anredera cordifolia (Ten.) Steenis leaves improved wound healing in guinea pigs," Universa Medicina, vol. 31, no. 1, pp. 4-11, Jan-Apr 2012

[6]. F. Starr, K. Starr, L. Loope, Anredera cordifolia, United States Geological Survey-Biological Resources Division, Hawai, 2003. Available: http://www.hear.org/Pier/pdf/pohreports/anredera_cordifolia.pdf (Accessed: June 23, 2017)

[7]. Indonesia Food and Drugs Federation (Badan Pengawas Obat dan Makanan RI (BPOM RI)). Anderdera cordifolia (Ten.) Steenis in Indonesia Original Drugs Directory, pp.10, BP POM RI, 2008. Available at: http://perpustakaan.pom.go.id/ebook/Taksonomi%20Koleksi%20Tanaman%20Obat%20Kebun%20Tanaman%20Obat%20Citeureup/Anredera%20cordifolia%C2%A0%C2%A0(Ten.)%20Steenis.pdf (Accessed: September 25, 2017)

[8]. Muhlisah F, The original rhizomes Indonesia and its benefits as a drug (Temu-temuan dan empon-empon budidaya dan manfaatnya), Yogyakarta: Kanisius; 2005.

[9]. S.M. Astuti, A.M.M. Sakinah, B.M.R. Andayani, A. Risch, "Determination of Saponin Compound from Anredera cordifolia (Ten) Steenis Plant (Binahong) to Potential Treatment for Several Diseases," J. Agric. Sci. vol. 3, no. 4, pp. 224-32, 2011.

[10]. T.E. Tshikalange, J.J.M. Meyer, A.A. Husein, "Antimicrobial activity, toxicity and the isolation of a bioactive compound from plants used to treat sexually transmitted diseases," J. Ethnopharmacology, vol. 96, no. 3, pp. 515-19, Jan 2005.
Available at: http://dx.doi.org/10.1016/j.jep.2004.09.057

[11]. S. Sumartiningsih, " The effect of Binahong to hematoma," International Journal of Medical, Health, Biomedical, Bioengineering and Pharmaceutical Engineering, vo. 5, no. 6, pp. 244-6, 2011.

[12]. E.Y. Sukandar, I. Fidranny, L.F. Adiwibowo," Efficacy of ethanol extract of Anredera cordifolia (Ten) Steenis leaves on improving kidney failure in rats," Int J of Pharmacol, vol. 7, no. 8, pp. 850-5, 2011.

[13]. E.Y. Sukandar, A. Qowiyyah, L. Larasari, "Effect of Methanol Extract Hearleaf Madeiravine (Anredera cordifolia (Ten.) Steenis) Leaves on Blood Sugar in Diabetes Mellitus Model Mice", J Med Planta, vol 1, no. 4, pp. 1-10, Oct 2011.

[14]. S. Burgalassi, G. Perini, B. Giannaccin, M.F. Saettoni, A. Lodi, " Formulation and stability of suspensions for preclinical study," Boll. Chim. Farm, vol. 136, no. 10, pp. 628-34, Nov 1991.

[15]. T.P. Danielle dos Santos, H.M. Maria, at al., "Methodology Report Development of Animal Model for Studying Deep Second-Degree Thermal Burns," J. Biomed. Biotechnol., vo. 2012, pp. 1-7, March 2012.

[16]. S.W. Lim, S.P. Hong, et al., "Simultaneous effect of ursolic acid and oleanolic acid on epidermal permeability barrier function and epidermal keratinocyte differentiation via peroxisome proliferator-activated receptor-α," J. Dermatol, vol 34, no. 9, pp. 625-634, Sep 2007.

[17]. Ueda Clarence T, Vinod PS, Kris D, et al, Topical and Transdermal Drug Product. The United States Pharmacopeial, Inc, Canada: Wiley, 2009.

[18]. S. Dhivya, V.P. Vismanadha, S. Elango," Wound Dressings- a review," BioMedicine, vol. 5, no. 4, pp. 24-28, 2015.

[19]. D.E. Tsala, D. Amadou, S. Habtemariam," Natural Wound Healing and Bioactive Natural Products," Phytopharmacology, vol. 4, no.3, pp. 532-60, March 2013.

[20]. A. Zimna, K. Maceijk, "Hypoxia-Inducible Factor-1 in Physiological and Pathophysiological Angiogenesis: Applications and Therapies," BioMed. Res. Int, vol. 2015, pp. 1-13, Apr 2015.

[21]. A. Parihar, M.S. Parihar, S. Milner, S. Bhat, " Oxidative stress and anti-oxidative mobilization in burn injury" J.burns, vol. 34, no. 1, pp. 6-17, 2017.

[22]. M. Pakyari, A. Farrokhi, M.K. Maharlooei, A. Ghahary, "Critical Role of Transforming Growth Factor Beta in Different Phases of Wound Healing," Advances in Wound Care, vol. 2, no. 5, pp. 215–24, Jun 2013.